

Guiding Principles for Chronic Total Occlusion Percutaneous Coronary Intervention

A Global Expert Consensus Document

ABSTRACT: Outcomes of chronic total occlusion (CTO) percutaneous coronary intervention (PCI) have improved because of advancements in equipment and techniques. With global collaboration and knowledge sharing, we have identified 7 common principles that are widely accepted as best practices for CTO-PCI.

1. Ischemic symptom improvement is the primary indication for CTO-PCI.
2. Dual coronary angiography and in-depth and structured review of the angiogram (and, if available, coronary computed tomography angiography) are key for planning and safely performing CTO-PCI.
3. Use of a microcatheter is essential for optimal guidewire manipulation and exchanges.
4. Antegrade wiring, antegrade dissection and reentry, and the retrograde approach are all complementary and necessary crossing strategies. Antegrade wiring is the most common initial technique, whereas retrograde and antegrade dissection and reentry are often required for more complex CTOs.
5. If the initially selected crossing strategy fails, efficient change to an alternative crossing technique increases the likelihood of eventual PCI success, shortens procedure time, and lowers radiation and contrast use.
6. Specific CTO-PCI expertise and volume and the availability of specialized equipment will increase the likelihood of crossing success and facilitate prevention and management of complications, such as perforation.
7. Meticulous attention to lesion preparation and stenting technique, often requiring intracoronary imaging, is required to ensure optimum stent expansion and minimize the risk of short- and long-term adverse events.

These principles have been widely adopted by experienced CTO-PCI operators and centers currently achieving high success and acceptable complication rates. Outcomes are less optimal at less experienced centers, highlighting the need for broader adoption of the aforementioned 7 guiding principles along with the development of additional simple and safe CTO crossing and revascularization strategies through ongoing research, education, and training.

**Emmanouil S. Brilakis,
MD, PhD
et al**

Full author list is available on page 428

Key Words: coronary occlusion
■ methods ■ percutaneous coronary
intervention ■ treatment outcome

© 2019 American Heart Association, Inc.

<https://www.ahajournals.org/journal/circ>

Chronic total occlusions (CTOs) are completely occluded coronary arteries with Thrombolysis In Myocardial Infarction 0 flow with an estimated duration of at least 3 months. In recent years, the success rates of CTO percutaneous coronary intervention (PCI) have substantially improved, in concert with the maturation and refinement of the key indications, equipment, and techniques for recanalization of occluded coronary arteries. Global collaboration and sharing of knowledge and techniques have led to the emergence of 7 key principles for the performance of CTO-PCI that can help training, clinical practice, and education in this field (Table 1).

This document was conceived during CTO-PCI meetings in 2018 (CTO Summit, Multi-Level CTO, and Euro-CTO). An initial document draft was created by a group of CTO-PCI experts from North America, Europe, and Japan. A total of 113 CTO-PCI experts from 56 countries were invited to participate, of whom 101 from 50 countries provided comments and approved the final document.

SYMPTOM IMPROVEMENT IS THE PRIMARY INDICATION FOR CTO-PCI

Two published randomized, controlled clinical trials^{1,2} and several observational studies³ have reported symptom improvement after successful CTO-PCI. The EuroCTO multicenter trial (A Randomized Multicentre Trial to Evaluate the Utilization of Revascularization or Optimal Medical Therapy for the Treatment of Chronic Total Coronary Occlusions) randomly assigned 396 patients to CTO-PCI versus optimal medical therapy alone. At 12 months, in comparison with patients randomly assigned to medical therapy only, patients randomly assigned to CTO-PCI had greater improvement in angina frequency (subscale change difference, 5.23; 95% CI, 1.75–8.71;

$P=0.003$) and quality of life (subscale change difference, 6.62; 95% CI, 1.78–11.46; $P=0.007$), as assessed with the Seattle Angina Questionnaire.¹ The single-center IMPACTOR-CTO trial (Impact on Inducible Myocardial Ischemia of Percutaneous Coronary Intervention versus Optimal Medical Therapy in Patients with Right Coronary Artery Chronic Total Occlusion) randomly assigned 94 patients with isolated right coronary artery CTO to CTO-PCI versus optimal medical therapy alone.² At 12 months, in comparison with optimal medical therapy, patients undergoing CTO-PCI had a significant reduction in ischemic burden and improvement in 6-minute walk distance and quality of life as assessed by the Short Form-36 Health Survey. Such symptomatic improvement confirms results from multiple observational studies and meta-analyses.^{4–6} Interpretation of randomized CTO-PCI trials should take into consideration selection bias, because the most symptomatic patients were less likely to be enrolled, and crossover between arms. For example, no symptomatic benefits were observed in a third randomized trial, DECISION CTO (Drug-Eluting Stent Implantation Versus Optimal Medical Treatment in Patients With Chronic Total Occlusion).⁷ However this study enrolled patients with minimal symptoms, and crossover rates were high in both treatment arms, moving the outcomes toward the null. In addition, no sham-controlled trial has yet been performed, leaving the possibility that some of the observed benefit of CTO-PCI is mediated by the placebo effect. One such trial is underway, the SHINE-CTO trial (Sham-controlled Intervention to Improve QOL in CTOs; NCT02784418).

In observational studies, CTO-PCI relieved regional ischemia and has been associated with improved exercise capacity, increased anaerobic threshold,⁸ and improvement in depression.⁹ Viable myocardium supplied by a CTO is a persistently ischemic zone.^{10,11} It remains undetermined whether CTO-PCI improves other cardiovascular outcomes, such as left ventricular ejection fraction, risk for arrhythmias, and mortality. Both regional and global left ventricular function improved after successful CTO-PCI in several carefully performed observational studies¹² using paired cardiac magnetic resonance imaging in patients with demonstrable viability or baseline dysfunction,¹³ but not in 2 randomized, controlled trials.^{14,15} These randomized studies, however, were performed in patients with normal mean left ventricular ejection fraction and did not examine the presence of viable dysfunctional myocardium at baseline, nor did they assess exercise-induced changes in left ventricular function. In patients with ischemic cardiomyopathy with reduced ejection fraction, the presence of ischemia and viability in the myocardium supplied by the CTO vessel should be confirmed before considering CTO revascularization. Patients with coronary CTOs who received an implantable cardioverter defibrillator for primary

Table 1. Key Principles on the Indications and Technique of Chronic Total Occlusion Percutaneous Coronary Intervention

1	The principal indication for CTO-PCI is to improve symptoms.
2	Dual coronary angiography and thorough, structured angiographic review should be performed in every case.
3	Use of a microcatheter is essential for guidewire support.
4	There are 4 CTO crossing strategies: antegrade wire escalation, antegrade dissection/reentry, retrograde wire escalation, and retrograde dissection/reentry.
5	Change of equipment and technique increases the likelihood of success and improves the efficiency of the procedure.
6	Centers and physicians performing CTO-PCI should have the necessary equipment, expertise, and experience to optimize success and minimize and manage complications.
7	Every effort should be made to optimize stent deployment in CTO PCI, including the frequent use of intravascular imaging.

CTO indicates chronic total occlusion; and PCI, percutaneous coronary intervention.

or secondary prevention had a higher risk for ventricular arrhythmias than patients with nonocclusive coronary artery disease.^{16,17} and a higher frequency of recurrent ventricular tachycardia after ablation¹⁸; there have been no randomized studies, however, examining whether CTO-PCI reduces the risk for subsequent arrhythmias. In observational studies, patients presenting with ST-segment–elevation acute myocardial infarction and a CTO in a nonculprit coronary artery had higher risk for developing cardiogenic shock and higher mortality.¹⁹

In several observational studies of successful versus failed CTO-PCI, patients with successful procedures had lower mortality than those who had unsuccessful procedures, but observational studies are subject to bias.^{4,20} Observational studies have also demonstrated a lower incidence of major adverse cardiac events with CTO-PCI^{21,22} in comparison with medical therapy alone, even among patients with well-developed collateral circulation.²³ Although CTO-PCI may improve hard outcomes, especially in patients with large ischemic burden (eg, ischemia of >10% of the myocardium) in whom complete revascularization is achieved,^{24,25} this hypothesis will require confirmation in well-designed, prospective, randomized, controlled clinical trials, such as the ongoing ISCHEMIA-CTO trial (Nordic and Spanish Randomized Trial on the Effect of Revascularization or Optimal Medical Therapy of Chronic Total Coronary Occlusions With Myocardial Ischemia; NCT03563417) and the NOBLE-CTO study (Nordic-Baltic Randomized Registry Study for Evaluation of PCI in Chronic Total Coronary Occlusion; NCT03392415).

In the 2011 American College of Cardiology/American Heart Association PCI guidelines, CTO-PCI carries a class IIA/level of evidence B recommendation: “PCI of a CTO in patients with appropriate clinical indications and suitable anatomy is reasonable when performed by operators with appropriate expertise.”²⁶ The 2018 European Society of Cardiology/European Association of Cardiothoracic Surgery guidelines on myocardial revascularization CTO-PCI carries a class IIA/level of evidence B recommendation: “Percutaneous recanalization of CTOs should be considered in patients with angina resistant to medical therapy or with large area of documented ischemia in the territory of the occluded vessel.”²⁷ In summary, improving patient symptoms caused by myocardial ischemia (angina, exertional dyspnea, and sometimes fatigue) despite optimal medical therapy remains the only benefit of CTO-PCI that has been demonstrated in randomized, controlled trials and should therefore currently be the primary indication for offering this procedure to patients. An office-based risk/benefit conversation with prospective patients undergoing CTO-PCI is strongly encouraged to provide realistic expectations before the procedure.

DUAL ANGIOGRAPHY AND DETAILED, STRUCTURED ANGIOGRAPHIC REVIEW

The simplest, yet most powerful technique for improving technical success and reducing complications of CTO-PCI is the performance of high-quality, simultaneous dual coronary angiography. The use of 2 catheters and pressure-monitoring systems adds little time and cost to the procedure. Dual coronary angiography allows better visualization and understanding of CTO anatomy and is pivotal in estimating the complexity of the lesion and the likelihood of success. Moreover, it improves procedural safety by elucidating the guidewire location during crossing attempts and facilitating the management of periprocedural complications, such as perforation. CTO-PCI with a single guide can be performed in selected cases with collateral circulation exclusively coming from ipsilateral vessels, for example, in CTOs located in a left dominant system.²⁸ In the latter scenario, selective contrast injection in the collateral donor branch through a microcatheter can be performed to reduce contrast administration and to avoid propagation of antegrade dissection zones. The ping-pong technique, ie, the use of 2 catheters in the left main coronary artery, will allow for easier guidewire and microcatheter management, especially when using a retrograde approach.

Before the procedure, a detailed review and analysis of the angiogram and, if available, coronary computed tomography angiography (CCTA) is essential for creating a primary and secondary procedural plan and assessing the risk/benefit ratio of the procedure. To allow adequate time for procedural planning and preparation and for proper counseling of patients, ad hoc CTO-PCI is discouraged in most cases. CTO-PCI preplanning can also help minimize contrast and radiation dose, reduce patient and operator fatigue, allow additional evaluation (such as myocardial viability) to be performed, and enable detailed discussion with the patient about all the aspects of the CTO-PCI procedure.

CTO anatomy will dictate the most likely successful and safest crossing strategies. Angiographic review of the CTO anatomy focuses on 4 characteristics (Figure 1): (1) proximal cap morphology; (2) occlusion length, course, and composition (eg, calcium); (3) quality of the distal vessel; and (4) characteristics of the collateral circulation.^{29,30} Moreover, non-CTO lesions are reviewed, because assessing intermediate left main or other lesions may change clinical decision making leading to alternative revascularization strategies, such as coronary artery bypass graft surgery or pre-CTO-PCI stenting of a donor artery.

Proximal Cap Morphology

Determining the location and morphology of the proximal cap is critical for selecting an optimal approach to

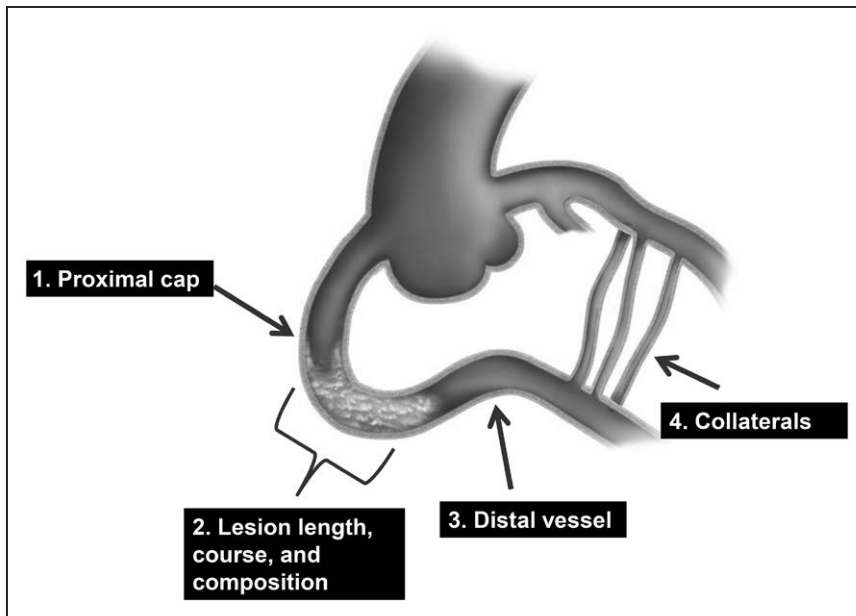


Figure 1. The 4 key angiographic parameters that need to be assessed to plan chronic total occlusion percutaneous coronary intervention.

Reproduced from Brilakis³⁰ with permission. Copyright © 2017, Elsevier.

CTO-PCI. Attempts to cross ambiguous proximal caps may lead to perforation. Additional angiographic projections using dual injection, selective contrast injection through a microcatheter located near the proximal cap, use of intravascular ultrasound,³¹ or preprocedural or real-time CCTA coregistration³² may help clarify the location of the proximal cap.³³ If proximal cap ambiguity cannot be resolved, a retrograde approach is often recommended as primary strategy.

Lesion Length, Course, and Composition

Lesion length is often overestimated with antegrade-only injections because of underfilling and poor opacification of the distal vessel, from competing antegrade and retrograde coronary flow, leaving uncertainty about the location and morphology of the distal cap. Dual injection or preprocedural CCTA³⁴ allows more accurate estimation of CTO length and the distal cap anatomy. Severe calcification and tortuosity of the occluded segment can hinder CTO crossing and increase the likelihood of subadventitial guidewire entry. Advancing a knuckled (J-shaped) guidewire or changing to the retrograde approach is often preferred when the vessel course is unclear or highly tortuous,³⁵ because such a J-shaped or knuckled wire allows advancement within the vessel architecture with a low risk of perforation.³⁶

Distal Vessel

A distal vessel of large caliber (>2.0 mm) that fills well does not have significant disease and is free from major branches facilitates CTO recanalization. Conversely, small, diffusely diseased distal vessels are more challenging to recanalize, especially after subintimal guidewire entry. In some cases, however, distal vessels are

small because of hypoperfusion, leading to negative remodeling, and will increase in size after recanalization.³⁷ Distal CTO caps in native coronary artery CTOs are more likely to be calcified and resistant to guidewire penetration in patients with previous coronary artery bypass grafting. Moreover, distal vessel calcification may hinder wire reentry in case of subintimal guidewire entry.

Collateral Circulation

Evaluation of the collateral circulation is critical for determining the feasibility of the retrograde approach.³⁸ High-quality angiography (ideally obtained during breath hold and without panning), allowing complete opacification of collateral vessels and obtained in optimal angiographic projections, should therefore be encouraged as part of the routine diagnostic studies when a CTO is found. Retrograde access to the distal vessel can be obtained via septal collaterals, epicardial collaterals, or (patent or occluded) coronary bypass grafts. When assessing collateral channels, it is important to consider size, tortuosity, bifurcations, angle of entry to and exit from the collateral, and distance from the collateral exit to the distal cap. The most important predictor of successful guidewire and device crossing is lack of tortuosity, followed by size.³⁹ The size of the collaterals is often assessed by using the Werner classification (CC0, no continuous connection; CC1, threadlike connection; and CC2, side branch-like connection).¹⁰ Crossing invisible septal collateral channels is often possible with the surfing technique, letting the wire find the path of least resistance.⁴⁰ It is helpful to carefully study previous angiograms for multiple potential collateral pathways, because the predominant collateral may change over the time before the procedure or during the course of

PCI (shifting collaterals). Previously visualized collaterals that disappear at the time of the procedure may still be crossable. Whenever required, and after ensuring adequate backflow to prevent barotrauma, selective contrast tip injections through the microcatheter can be safely performed to outline collateral anatomy. Patent bypass grafts represent an ideal retrograde conduit because of the absence of side branches, predictable course, and large caliber. Even occluded grafts can be used as retrograde pathways. However, in case of collateral circulation originating from the left anterior descending artery, that is supplied by a mammary artery, access via the internal mammary artery graft increases the risk of global ischemia and should be avoided whenever possible.⁴¹

Septal collaterals are typically safer and easier to navigate using very soft tip and polymer-jacketed guidewires in comparison with epicardial collaterals.^{42,43} In contrast to epicardial collaterals, septal collaterals can be safely dilated with small balloons to facilitate microcatheter or device crossing if required. The donor vessel proximal to the collateral origin, and collateral dominance (ie, presence of a single large visible collateral), should also be assessed during retrograde procedures to determine the risk for ischemia during retrograde crossing attempts. Careful review of collaterals before the procedure can reduce contrast and radiation dose, and the duration of the procedure. In cases where the collateral anatomy is unclear or ambiguous, it can be helpful to perform selective injection of contrast into the collateral through the center lumen of a microcatheter placed into the collateral by using a 2- to 3-mL syringe. Furthermore, in cases where unfavorable noninterventional epicardial collaterals provide the dominant blood flow to the CTO, it can be useful to balloon occlude the epicardial collateral for 2 to 4 minutes to see if more favorable interventional collaterals can be recruited and identified for attempts at retrograde crossing.

CTO Scores

Angiographic and clinical characteristics, such as previous CTO-PCI failure⁴⁴ and previous coronary artery bypass grafting,⁴⁵ have been combined to create scores for estimating the difficulty and hazard of a specific CTO-PCI in various patient populations. The first and most commonly used CTO-PCI score is the J-CTO score (Multicenter CTO Registry of Japan), developed to estimate the likelihood of successful antegrade guidewire crossing within 30 minutes based on 5 criteria (at least 1 bend of $>45^\circ$ in the CTO entry or CTO body, occlusion length >20 mm, calcification, blunt proximal stump, and previously failed attempt).⁴⁶ The J-CTO score has been validated in other CTO-PCI cohorts⁴⁴ and is also associated with 1-year clinical outcomes.⁴⁷ Other scores

include the PROGRESS-CTO score,⁴⁸ the RECHARGE (Registry of Crossboss and Hybrid Procedures in France, the Netherlands, Belgium and United Kingdom) registry score,⁴⁹ the CL-score (Clinical and Lesion related score),⁵⁰ the ORA (ostial location, collateral filling of Rentrop <2 , age >75) score,⁵¹ the Ellis et al⁵² score, the weighted angiographic scoring model (W-CTO score),⁵³ and the CASTLE (coronary artery bypass grafting history, age ≥ 70 years], stump anatomy [blunt or invisible], tortuosity degree [severe or unseen], length of occlusion ≥ 20 mm], and extent of calcification [severe]) score.⁵⁴ There are also CCTA-based scores, such as the CT-RECTOR multicenter registry (Computed Tomography Registry of Chronic Total Occlusion Revascularization) score⁵⁵ and the Korean Multicenter CTO CT Registry Score.⁵⁶ Various scores have similar predictive capacity for technical success and are more accurate in antegrade-only cases.⁵⁷ The risk of complications can be assessed by using the Progress-CTO complications score that uses 3 variables (age ≥ 65 years, lesion length >23 mm, and use of the retrograde approach) to stratify patients for the risk of periprocedural complications.⁵⁸

In general, each score is only applicable to the population from which it was derived and validated. Calculating ≥ 1 scores can promote detailed review of the angiogram and facilitate decision making. For example, medical therapy may be preferred over CTO-PCI in mildly symptomatic patients with highly complex occlusions. Complex CTOs (such as those with J-CTO score ≥ 2) are more likely to require dissection reentry and retrograde crossing techniques and should be performed by experienced operators.

USE OF A MICROCATETER FOR GUIDEWIRE MANIPULATION

A microcatheter should be routinely used for supporting the coronary guidewire and allowing rapid guidewire switching during both antegrade and retrograde wire manipulation. Microcatheters improve the precision of both rotational and longitudinal guidewire movements both in fluid (blood-filled vessels) and in tissue (the occlusion itself) and allow the penetration force of the wire to be dynamically altered by changing the distance between the tip of the guidewire and the microcatheter, with guidewires becoming stiffer when the microcatheter is positioned close to the guidewire tip. Microcatheters also allow rapid guidewire tip reshaping or exchange, while preserving previous guidewire crossing or advancement achieved. Microcatheters inherently dilate retrograde collateral channels and protect them from wire-induced trauma. Microcatheters can also be used to deliver contrast either for visualization or to accomplish the Carlino technique (intralesional injection of 1–2 mL of contrast to elucidate microcatheter posi-

tion and facilitate crossing), especially in wire-resistant lesions.⁵⁹ A microcatheter is preferred over an over-the-wire balloon because it has a marker at the distal tip, providing adequate fluoroscopic feedback of its actual position and also providing greater freedom of advancement with a lower profile and better wire-to-lumen internal diameter ratio. Also, unlike over-the-wire plastic balloon catheter shafts that are prone to kinking, nearly all contemporary coronary microcatheters incorporate a kink-resistant metallic braid.

Similar to guidewires, microcatheter selection depends on the CTO angiographic characteristics, local availability, and expertise. In addition to using a microcatheter, obtaining coaxial guide position and strong guide support can significantly facilitate CTO crossing.

CTO CROSSING STRATEGIES

There are 4 CTO crossing strategies, classified according to wiring direction (antegrade and retrograde) and whether or not the subintimal space is used (wiring versus dissection and reentry; Figure 2).^{29,30}

Antegrade Wiring

Antegrade wiring (also called antegrade wire escalation) is the most widely used CTO crossing technique.^{31,60–62} Various guidewires are advanced in the antegrade direction (original direction of blood flow). Guidewire choice depends on CTO characteristics. If there is a tapered proximal cap or a functional occlusion with a visible channel, a polymer-jacketed, low penetration force, tapered guidewire is used initially, with subsequent escalation to intermediate and high penetration force guidewires, as required. If there is a blunt proximal cap, antegrade wiring is usually started with an intermediate penetration force polymer-jacketed guidewire, or a composite core guidewire. Stiff, high penetration force guidewires may be required in highly resistant proximal caps or when areas of resistance are encountered within the body of the occlusion. After proximal cap crossing of 1 to 2 mm, however, deescalation to less penetrating guidewires should follow to navigate through the CTO segment.

Contralateral injection and orthogonal angiographic projections are critical for determining guidewire position during crossing attempts. If the guidewire enters into the distal true lumen, the microcatheter is then advanced into the distal true lumen, and the dedicated CTO guidewire is then exchanged for a workhorse guidewire through the microcatheter to minimize the risk for distal vessel injury and perforation during balloon angioplasty and stenting (wire deescalation). If the guidewire exits the vessel structure, it should be withdrawn and redirected without advancing microcatheters, balloons, or stents over it. If the guidewire

enters the subintimal space, it can be redirected, but if this maneuver fails, the wire can be left in place to aid directing a second guidewire into the distal true lumen (parallel-wire technique), which can be assisted by a dual-lumen microcatheter or facilitated by the use of intravascular ultrasound.³¹ Alternatively, antegrade dissection/reentry techniques can be used to reenter into the distal true lumen, as described below. Subintimal guidewire advancement distal to the distal cap should be avoided because it can lead to hematoma formation, causing luminal compression and reducing the likelihood of success. Antegrade vessel reentry can be guided by intravascular ultrasound, although this approach requires expertise and may be hindered by limited wire maneuverability in the presence of the subintimal intravascular ultrasound catheter.

Antegrade Dissection and Reentry

Antegrade dissection and reentry involves entering the subintimal space, followed by subintimal crossing of the CTO with subsequent reentry into the distal true lumen. Antegrade dissection and reentry may be intentional or unintentional during antegrade wiring attempts. The first developed dissection reentry technique was named STAR (Subintimal Tracking And Re-Entry) and used inadvertent, uncontrollable reentry into the distal lumen.⁶³ This frequently necessitated stenting long coronary segments with occlusion of numerous side branches, leading to extensive vascular injury and high rates of in-stent restenosis and reocclusion.^{63–65} As such, the STAR technique has evolved to a bailout strategy without stent implantation after ballooning, in preparation for a repeat CTO-PCI attempt (subintimal plaque modification, also termed an “investment procedure”).^{66–68} The development of limited dissection/reentry techniques (using dedicated reentry systems^{69,70} or wire-based strategies⁷¹) was an important advancement, because they minimize vascular injury, limit the length of dissection and subsequent stent length, and increase the likelihood of side branch preservation.^{36,69,72} Such approaches have been associated with favorable clinical outcomes.^{72–76}

Retrograde Approach

The retrograde technique differs from the antegrade approach in that the occlusion is approached from the distal vessel with guidewire advancement against the original direction of blood flow.⁷⁷ A guidewire is advanced into the artery distal to the occlusion through a collateral channel or through a bypass graft, followed by placement of a microcatheter at the distal CTO cap. Retrograde CTO crossing is then attempted either with retrograde wiring (usually for short occlusions, especially when the distal cap is tapered⁷⁸) or using retrograde dissection/reentry techniques.

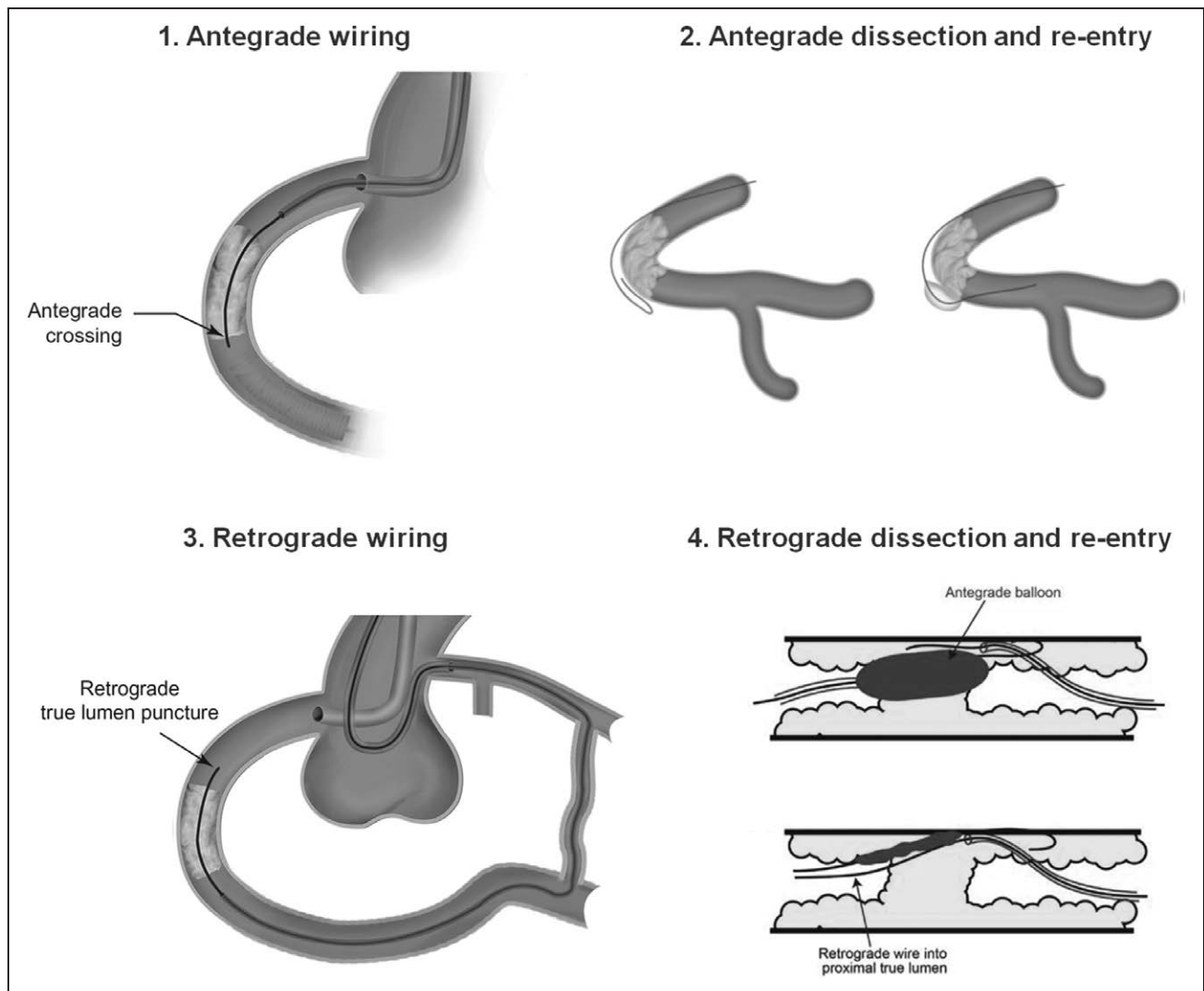


Figure 2. Illustration of the chronic total occlusion crossing techniques. Reproduced from Brilakis³⁰ with permission. Copyright © 2017, Elsevier.

The most commonly used retrograde crossing technique is reverse controlled antegrade and retrograde tracking, in which a balloon is inflated over the antegrade guidewire, followed by retrograde guidewire advancement into the space created by the antegrade balloon (Figure 2). In challenging reverse controlled antegrade and retrograde tracking cases, intravascular ultrasound can clarify the mechanism of failure and increase the likelihood of success.⁷⁹ Guide catheter extensions can also facilitate reverse controlled antegrade and retrograde tracking.⁸⁰

Crossing Strategy Selection

Selecting the initial and subsequent crossing strategies depends on the CTO lesion characteristics and local equipment availability and expertise.

Several algorithms have been developed to facilitate crossing strategy selection, such as the hybrid,²⁹

Asia Pacific,³⁵ and Euro-CTO⁸¹ algorithms. Antegrade crossing is generally preferred over retrograde crossing as the initial crossing strategy, given the higher risk of complications with the retrograde approach^{60–62} and the need for antegrade lesion preparation even when the retrograde approach is eventually required. Some retrograde CTO-PCI complications, however, are caused by antegrade crossing attempts. The retrograde approach remains critical for achieving high success rates, especially in more complex CTOs,^{60,62} and has been associated with favorable long-term outcomes.⁸²

CTOs with proximal cap ambiguity and flush aorto-ostial CTOs are often approached with a primary retrograde strategy. Alternatively, proximal cap ambiguity can be approached in the antegrade direction, especially when no collateral or graft is available by using (1) intravascular ultrasound or preprocedural CCTA for determining the location of the proximal cap and vessel course,^{32,35,83} or (2) techniques to facilitate entry into

the subintimal space proximal to the occlusion, such as the balloon-assisted subintimal entry (ie, inflation of a balloon proximal to the occlusion to cause a dissection, followed by subintimal guidewire entry and subintimal crossing of the occlusion) technique.⁸⁴

CHANGE OF CROSSING STRATEGY

Flexibility is important for the success, safety, and efficiency of CTO-PCI. If the initial or subsequent crossing strategy fails to achieve progress, small changes (such as modifying the guidewire tip angulation or changing guidewire) or more significant changes (such as converting from an antegrade to a retrograde approach) should be made, based on preprocedural planning.^{29,35} It is important to avoid getting stuck in a failure mode, in which excessive time, radiation, and contrast are expended with little or no progress being made while repeatedly attempting the same technique, because this will preclude the use of alternative strategies and increase the risk of complications.

Similar to selection of the initial crossing strategy, the timing and choice of subsequent crossing strategies depends on lesion characteristics, challenges encountered with the original technique, and equipment availability and expertise, and can be guided by existing crossing algorithms.^{29,35} Only ~50% to 60% of CTOs are successfully crossed with the initial strategy,^{28,60,61} highlighting the need for further refinements in the procedure-planning algorithms. Changing strategies can help maximize the likelihood of eventual success and limit contrast volume and radiation dose.

Reasons to stop a CTO-PCI attempt include occurrence of a complication, high radiation dose (usually >5 Gy air kerma dose in the absence of lesion crossing or substantial progress), large contrast volume ad-

ministration (>3.7× the estimated creatinine clearance), exhaustion of crossing options, or patient or physician fatigue. As with all interventions, careful assessment of individual risk versus benefit should guide decision making and choice of strategy during different stages of the procedure. On many occasions, it may be best to fail rather than to pursue highly aggressive strategies that may lead to serious complications.⁶⁰

EQUIPMENT AND PHYSICIAN TEAM EXPERTISE

CTO-PCI should be performed within dedicated programs that promote continual training and rigorous monitoring of outcomes.⁸⁵ Higher CTO-PCI volume has consistently been associated with higher success rates.^{52,86,87}

The performance of CTO-PCI by a skilled physician and team is especially important to minimize and manage procedural complications. CTO-PCI carries increased risk of complications in comparison with non-CTO-PCI,⁸⁶ especially perforation.³ Across multiple contemporary registries, tamponade occurred in 0.4% to 1.3% of cases (Table 2).^{3,31,60–62,88,89} Additional CTO-PCI adverse events include access site complications, donor vessel injury, arrhythmias, stroke, contrast-induced nephropathy, radiation dermatitis, emergency coronary bypass graft surgery, and death.⁹⁰ The average complication risk is ~3%, but varies widely between studies (Table 2) and increases with greater lesion complexity.^{3,60–62,88,89}

Dual injection minimizes the risk for perforation by helping determine guidewire position. Placement of a safety guidewire in the CTO donor vessel can facilitate treatment if donor vessel injury occurs. Maintaining an activated clotting time of ≥300 to 350 seconds reduces

Table 2. Contemporary Series of Chronic Total Occlusion Percutaneous Coronary Intervention

Authors	Acronym	Study Period	Centers	Cases	Technical Success	Procedural Success	Overall MACE	Death	Acute MI	Stroke	TVR	Tamponade
Konstantinidis et al ⁸⁹	EURO-CTO registry	2008–2015	53	17 626	85%	–	0.6%	0.2%	–	–	–	0.4%
Habara et al ⁸⁸	Japanese Retrograde Summit Registry	2012–2013	56	3229	–	88%	0.5%	0.2%	0.1%	0.1%	–	0.3%
Tajti et al ⁶⁰	PROGRESS-CTO	2012–2017	20	3055	87%	85%	3.0%	0.3%	0.7%	0.1%	0.2%	0.5%
Suzuki et al ³¹	Japanese CTO-PCI Expert Registry	2014–2015	41	2846	90%	89%	<2%	0.2%	1.2%	0.2%	0.2%	0.4%
Maeremans et al ⁶¹	RECHARGE	2014–2015	17	1253	89%	86%	2.6%	0.2%	0.2%	2.2%	0.1%	1.3%
Wilson et al ⁶²	UK Hybrid	2012–2014	7	1156	90%	—	1.6%	0.0%	0.8%	0.4%	0.0%	0.7%
Sapontis et al ³	OPEN-CTO	2013–2017	12	1000	86%	85%	7.0%	0.9%	2.6%	0.0%	0.1%	–

The studies are listed according to the number of patients included. EURO-CTO indicates European Registry of Chronic Total Occlusion; MACE indicates major adverse cardiac events; MI, myocardial infarction; OPEN CTO, Outcomes, Patient Health Status, and Efficiency in Chronic Total Occlusion Hybrid Procedures; PROGRESS-CTO, Prospective Global Registry for the Study of Chronic Total Occlusion Intervention; RECHARGE, Registry of Crossboss and Hybrid procedures in France, The Netherlands, Belgium, and United Kingdom; UK hybrid, United Kingdom hybrid registry; and TVR, target vessel revascularization.

the risk of donor vessel thrombosis; the activated clotting time should be checked at least every 30 minutes during the procedure. In case of perforation, covered stents and coils should be available to treat large vessel and distal vessel perforations, respectively. Preprocedural operator training in the proper use of these devices will ensure efficient use in the emergency setting. In case of epicardial collateral perforation,^{43,91} embolization from both directions (using coils, thrombin, fat, etc) is often needed to achieve sealing.⁹² Special attention should be given to patients with previous coronary bypass graft surgery, because perforation can result in life-threatening, difficult to access, loculated hematomas⁹³ or bleeding in the mediastinum or pleural cavities.

Meticulous attention should also be paid to minimizing radiation dose and the risk for radiation skin injury. This can be achieved by using low-frame rate fluoroscopy and the fluoroscopy-store function for documenting balloon and stent inflation instead of cine-angiography, using collimation, minimizing the distance of the image receptor from the patient, and intermittently changing the position of the image receptor during the procedure.^{94,95} Patients who receive high doses of radiation (eg, >5 Gray air kerma dose) require formal follow-up to evaluate for subacute skin injury. Similarly, contrast administration should be minimized through meticulous preprocedural planning and use of contrast-sparing devices to reduce the risk for contrast nephropathy.

OPTIMAL STENT DEPLOYMENT

CTO-PCI often involves placement of multiple stents in vessels that are calcified, diffusely diseased, and negatively remodeled. Given the often arduous and lengthy attempts required for CTO crossing, less attention may be given to stent optimization (maximal stent expansion and optimal inflow and outflow), potentially resulting in higher rates of restenosis and stent thrombosis. Full lesion expansion should be achieved before stent implantation by predilation with properly sized balloon or atherectomy. Intravascular imaging can facilitate the assessment of vessel size and calcification before stenting and the adequacy of stent expansion, apposition and lesion coverage, to reduce the risk for subsequent adverse events.^{96–99} Moderate diffuse disease distal to the CTO often does not require treatment, because the distal vessel often enlarges over time after restoring vessel patency.¹⁰⁰

CONCLUSIONS

Extensive interactions and collaboration across the world have led to the advancements in CTO-PCI that are summarized in the 7 key principles outlined in this

global expert consensus document. These principles can guide training of new CTO-PCI operators and program development and facilitate further improvement in the success, safety, and clinical outcomes of CTO-PCI.

ARTICLE INFORMATION

Authors

Emmanouil S. Brilakis, MD, PhD; Kambis Mashayekhi, MD; Etsuo Tsuchikane, MD, PhD; Nidal Abi Rafeh, MD; Khaldoon Alaswad, MD; Mario Araya, MD; Alexandre Avran, MD; Lorenzo Azzalini, MD, PhD, MSc; Avtandil M. Babunashvili, MD; Baktash Bayani, MD; Ravinay Bhandi, MD; Nicolas Boudou, MD; Marouane Boukhris, MD; Nenad Ž. Božinović, MD; Leszek Bryniarski, MD, PhD; Alexander Bufe, MD; Christopher E. Buller, MD; M. Nicholas Burke, MD; Heinz Joachim Büttner, MD; Pedro Cardoso, MD; Mauro Carlino, MD; Evald H. Christiansen, MD; Antonio Colombo, MD; Kevin Croce, MD, PhD; Felix Damas de los Santos, MD; Tony De Martini, MD; Joseph Dens, MD, PhD; Carlo Di Mario, MD; Kefei Dou, MD; Mohamed Egred, MD; Ahmed M. ElGuindy, MD; Javier Escaned, MD, PhD; Sergey Furkalo, MD; Andrea Gagnor, MD; Alfredo R. Galassi, MD; Roberto Garbo, MD; Junbo Ge, MD; Pravin Kumar Goel, MD; Omer Goktekin, MD; Luca Grancini, MD; J. Aaron Grantham, MD; Colm Hanratty, MD; Stefan Harb, MD; Scott A. Harding, MD; Jose P.S. Henriques, MD; Jonathan M. Hill, MD; Farouq A. Jaffer, MD, PhD; Yangsoo Jang, MD; Risto Jussila, MD; Artis Kalnins, MD; Arun Kalyanasundaram, MD; David E. Kandzari, MD; Hsien-Li Kao, MD; Dimitri Karpaliotis, MD, PhD; Hussien Heshmat Kassem, MD, PhD; Paul Knaepen, MD; Ran Kornowski, MD; Oleg Krestyaninov, MD; A. V. Ganesh Kumar, MD; Peep Laanmets, MD; Pablo Lamelas, MD; Seung-Whan Lee, MD; Thierry Lefevre, MD; Yue Li, MD; Soo-Teik Lim, MD; Sidney Lo, MBBS; William Lombardi, MD; Margaret McEntegart, MD, PhD; Muhammad Munawar, MD; José Andrés Navarro Lecaro, MD; Hung M. Ngo, MD, PhD; William Nicholson, MD; Göran K. Olivecrona, MD, PhD; Lucio Padilla, MD; Marin Postu, MD; Alexandre Quadros, MD; Franklin Hanna Quesada, MD; Vithala Surya Prakasa Rao, MD; Nicolaus Reifart, MD; Meruzhan Saghatelian, MD; Ricardo Santiago, MD; George Sianos, MD, PhD; Elliot Smith, MD; James C. Spratt, MD; Gregg W. Stone, MD; Julian W. Strange, MD; Khalid Tammam, MD, PhD; Imre Ungi, MD, PhD; Minh Vo, MD; Vu Hoang Vu, MD; Simon Walsh, MD; Gerald S. Werner, MD; Jason R. Wollmuth, MD; Eugene B. Wu, MD; R. Michael Wyman, MD; Bo Xu, MD; Masahisa Yamane, MD; Luiz F. Ybarra, MD; Robert W. Yeh, MD; Qi Zhang, MD; Stéphane Rinfret, MD, SM

Correspondence

Emmanouil S. Brilakis, MD, PhD, Minneapolis Heart Institute, 920 E 28th St #300, Minneapolis, MN 55407. Email esbrilakis@gmail.com

Affiliations

Minneapolis Heart Institute and Minneapolis Heart Institute Foundation, Abbott Northwestern Hospital, MN (E.S.B., M.N.B.). Department of Cardiology and Angiology II University Heart Center Freiburg Bad Krozingen, Germany (K.M., H.J.B.). Toyohashi Heart Center, Aichi, Japan (E.T.). St. George Hospital University Medical Center, Beirut, Lebanon (N.A.R.). Henry Ford Hospital, Detroit, MI (K.A.). Clinica Alemana and Instituto Nacional del Tórax, Santiago, Chile (M.A.). Arnault Tzank Institut St. Laurent Du Var Nice, France (A.A.). Interventional Cardiology Division, Cardio-Thoracic-Vascular Department, San Raffaele Scientific Institute, Milan, Italy (L.A., M.C.). Department of Cardiovascular Surgery, Center for Endosurgery and Lithotripsy, Moscow, Russian Federation (A.M.B.). Cardiology Department, Mehr Hospital, Mashhad, Iran (B.B.). Department of Cardiology, Royal North Shore Hospital and Kolling Institute, University of Sydney, Australia (R.B.). Rangueil University Hospital, Toulouse, France (N.B.). Cardiology department, Abderrahment Mami Hospital, Faculty of Medicine of Tunis, University of Tunis El Manar, Tunisia (M.B.). Department of Interventional Cardiology Clinic for Cardiovascular Diseases University Clinical Center Nis, Serbia (N.Z.B.). II Department of Cardiology and Cardiovascular Interventions Institute of Cardiology, Jagiellonian University Medical College, Cracow, Poland (L.B.). Department of Cardiology, Heartcentre Niederrhein, Helios Clinic Krefeld, Krefeld, Germany, Institute for Heart and Circulation Research, University of Cologne, Germany, and University of Witten/Herdecke, Witten, Germany (A.B.). St. Michael's Hospital, Toronto, ON, Canada (C.E.B.). Cardiology Department, Santa Maria University Hospital (CHULN), Lisbon Academic Medical Centre (CAML) and Centro Cardiovascular da Universidade de Lisboa (CCUL), Por-

tugal (P.C.). Department of Cardiology, Aarhus University Hospital, Denmark (E.H.C.). San Raffaele Hospital and Columbus Hospital, Milan, Italy (A.C.). Cardiovascular Division, Brigham and Women's Hospital, Boston, MA (K.C.). Interventional Cardiology Department, Instituto Nacional de Cardiología Ignacio Chávez Mexico City, Mexico (F.D.d.I.S.). SIU School of Medicine, Memorial Medical Center, Springfield, IL (T.D.M.). Department of Cardiology, Hospital Oost-Limburg, Genk, Belgium (J.D.). Structural Interventional Cardiology, Careggi University Hospital, Florence, Italy (C.D.M.). Center for Coronary Heart Disease, State Key Laboratory of Cardiovascular Disease, Fu Wai Hospital, and National Center for Cardiovascular Diseases, Chinese Academy of Medical Sciences and Peking Union Medical College, Beijing (K.D.). Freeman Hospital and Newcastle University, Newcastle upon Tyne, United Kingdom (M.E.). Department of Cardiology, Aswan Heart Center, Egypt (A.M.E.). National Heart and Lung Institute, Imperial College London, United Kingdom (A.M.E.). Hospital Clinico San Carlos IDISSC and Universidad Complutense de Madrid, Spain (J.E.). Department of Endovascular Surgery and Angiography, National Institute of Surgery and Transplantology of AMS of Ukraine, Kiev (S.F.). Department of Invasive Cardiology, Maria Vittoria Hospital, Turin, Italy (A.G.). Chair of Cardiology, Department of PROMISE, University of Palermo, Italy (A.R.G.). Director of Interventional Cardiology, San Giovanni Bosco Hospital, Turin, Italy (R.G.). Zhongshan Hospital, Fudan University, Shanghai, China (J.G.). Sanjay Gandhi Post Graduate Institute of Medical Sciences Lucknow, India (P.K.G.). Memorial Hospital, Istanbul, Turkey (O.G.). Centro Cardiologico Monzino, IRCCS, Milan, Italy (L.G.). Saint Luke's Mid America Heart Institute, Kansas City, MO (J.A.G.). Belfast Health and Social Care Trust, United Kingdom (C.H., S.W.). LKH Graz II, Standort West, Kardiologie, Teaching Hospital of the University of Graz, Austria (S.H.). Wellington Hospital, Capital and Coast District Health Board, New Zealand (S.A.H.). Academic Medical Centre of the University of Amsterdam, The Netherlands (J.P.S.H.). King's College Hospital, London, United Kingdom (J.M.H.). Cardiology Division, Massachusetts General Hospital, Boston (F.A.J.). Division of Cardiology, Severance Cardiovascular Hospital, Yonsei University Health System, Seoul, South Korea (Y.J.). Helsinki Heart Hospital, Finland (R.J.). Department of Cardiology, Eastern Clinical University Hospital, Riga, Latvia (A. Kalnins). Promed Hospital, Chennai, India (A. Kalyanasundaram). Piedmont Heart Institute, Atlanta, GA (D.E.K.). Department of Internal Medicine, National Taiwan University Hospital, Taipei (H.-L.K.). Columbia University, New York (D.K.). Cardiology Department, Kasr Al-Ainy Faculty of Medicine, Cairo University, Egypt (H.H.K.). Fujairah Hospital, United Arab Emirates (H.H.K.). Department of Cardiology, VU University Medical Center, Amsterdam, The Netherlands (P.K.). Department of Cardiology, Rabin Medical Center, Petach Tikva, "Sackler" School of Medicine, Tel Aviv University, Petach Tikva, Israel (R.K.). Meshalkin Novosibirsk Research Institute, Russia (O.K.). Department of Cardiology, Dr LH Hiranandani Hospital, Mumbai, India (A.V.G.K.). North Estonia Medical Center Foundation, Tallinn, Estonia (P. Laanmets). Department of Interventional Cardiology and Endovascular Therapeutics, Instituto Cardiovascular de Buenos Aires, Argentina (P. Lamelas). Department of Health Research Methods, Evidence and Impact, McMaster University, Hamilton, ON, Canada (P. Lamelas). Department of Cardiology, Asan Medical Center, University of Ulsan College of Medicine, Seoul, South Korea (S.-W.L.). Institut Cardiovasculaire Paris Sud Hôpital privé Jacques Cartier, Massy, France (T.L.). Department of Cardiology, the First Affiliated Hospital of Harbin Medical University, China (Y.L.). Department of Cardiology, National Heart Centre Singapore (S.-T.L.). Department of Cardiology, Liverpool Hospital and The University of New South Wales, Sydney, Australia (S.L.). University of Washington, Seattle (W.L.). Golden Jubilee National Hospital, Glasgow, United Kingdom (M. McEntegart). Binawaluya Cardiac Center, Jakarta, Indonesia (M. Munawar). Médico Cardiólogo Universitario - Hemodinámica en Hospital de Especialidades Eugenio Espejo y Hospital de los Valles, Ecuador (J.A.N.L.). Choray Hospital, Vietnam (H.M.N.). WellSpan Health System, York, PA (W.N.). Skane University Hospital, University of Lund, Sweden (G.K.O.). Department of Interventional Cardiology and Endovascular Therapeutics, ICBA, Instituto Cardiovascular, Buenos Aires, Argentina (L.P.). Cardiology Department, University of Medicine and Pharmacy "Carol Davila," Institute of Cardiovascular Diseases "Prof. Dr. C.C. Iliescu," Bucharest, Romania (M.P.). Instituto de Cardiología / Fundação Universitária de Cardiologia - IC/FUC, Porto Alegre, RS - Brazil (A.Q.). Interventional Cardiology Department, Clínica Com-familiar Pereira City, Colombia (F.H.Q.). Hyderguda Apollo, Hyderabad, India (V.S.P.R.). Department of Cardiology, Main Taunus Heart Institute, Bad Soden, Germany (N.R.). Nork-Marash Medical Center, Yerevan, Armenia (M.S.). Hospital Pavia Santurce, PCI Cardiology Group, San Juan, Puerto Rico (R.S.T.). AHEPA University Hospital, Thessaloniki, Greece (G.S.). Department of Cardiology, Barts Heart Centre, St Bartholomew's Hospital, London, United Kingdom (E.S.). St George's University Hospital NHS Trust, London, United Kingdom (J.S.). Center for Interventional Vascular Therapy, Division of Cardiology, New York-Presbyterian Hospital/Columbia University Medical Center (G.W.S.). Department of

Cardiology, Bristol Royal Infirmary, United Kingdom (J.W.S.). Cardiac Center of Excellence, International Medical Center, Jeddah, Saudi Arabia (K.T.). 2nd Department of Internal Medicine and Cardiology Center, University of Szeged, Hungary (I.U.). Mazankowski Alberta Heart Institute, Edmonton, AB, Canada (M.V.). Interventional Cardiology Department, Heart Center, University Medical Center at Ho Chi Minh City, and University of Medicine and Pharmacy, Vietnam (H.V.). Medizinische Klinik I Klinikum Darmstadt GmbH, Germany (G.W.). Providence Heart and Vascular Institute, Portland, OR (J.R.W.). Prince of Wales Hospital, Hong Kong (E.W.). Torrance Memorial Medical Center, CA (R.M.W.). Fu Wai Hospital, National Center for Cardiovascular Diseases, Chinese Academy of Medical Sciences, Beijing (B.X.). Saitima St. Luke's International Hospital, Tokyo, Japan (M.Y.). London Health Sciences Centre, Schulich School of Medicine & Dentistry, Western University, London, Ontario, Canada (L.F.Y.). Beth Israel Deaconess Medical Center, Boston, MA (R.W.Y.). Shanghai East Hospital, Tongji University, China (Q.Z.). McGill University Health Centre, McGill University, Montreal, QC, Canada (S.R.).

Acknowledgment

We recognize the assistance of Dr Iosif Xenogiannis in the creation of this document.

Disclosures

Dr Brilakis: Consulting/speaker honoraria from Abbott Vascular, American Heart Association (associate editor *Circulation*), Boston Scientific, Cardiovascular Innovations Foundation (Board of Directors), CSI, Elsevier, GE Healthcare, InfraRedx, and Medtronic; research support from Regeneron and Siemens. Shareholder: MHI Ventures. Board of Trustees: Society of Cardiovascular Angiography and Interventions. Dr Mashayekhi: Consulting/speaker/proctoring honoraria from Abbott Vascular, Ashai Intecc, AstraZeneca, Biotronik, Boston Scientific, Cardinal Health, Daiichi Sankyo, Medtronic, Teleflex, Terumo. Dr Tsuchikane: Consultant of Boston Scientific, Asahi Intecc, Nipro, and Kaneka. Dr Abi Rafeh: CTO Proctor and consultant for Boston Scientific and Abbott Vascular. Dr Alaswad: consultant and speaker for Boston Scientific, Abbott Cardiovascular, CSI, and LivaNova. Dr Avran: Proctor for Boston Scientific, Biotronik, Abbott, Terumo, Biosensor, Medtronic. Dr Azzalini: Honoraria from Abbott Vascular, Guerbet, Terumo, and Sahajanand Medical Technologies; research support from ACIST Medical Systems, Guerbet, Terumo. Dr Boudou: Proctorship fees from Boston Scientific, Terumo, Abbott Vascular, and Biotronik. Dr Buller: Intellectual property: Teleflex; consultant: Abbott Vascular, Soundbite Medical, and Philips-Volcano. Dr Burke: Consulting and speaker honoraria from Abbott Vascular and Boston Scientific. Dr Croce: Proctor/speaking honoraria: Abbott, Boston Scientific, CSI, Philips; research grant: Teleflex, Takeda; advisory board: Abiomed, Cordis. Dr de los Santos: Speaker and proctor of Boston Scientific, Terumo, and Abbott. Dr De Martini: Proctor and advisory board for Abbott and Boston Scientific. Dr Dens: Consulting/speaker honoraria from Abbott Vascular, Boston Scientific, IMDS, Orbus Neich, Terumo, and Topmedical (distributor for Asahi). Dr Di Mario: research grant to institution from Amgen, Behring, Chiesi, Daiichi Sankyo, Edwards, Medtronic, Shockwave. Dr Eged: Honoraria, speaker and proctorship fees from Abbott Vascular, Boston Scientific, Vascular Perspectives, Philips/Volcano, Biosensors, and EPS. Dr ElGuindy: Proctorship fees from Boston Scientific. Dr Gagnor: Consultant Boston Scientific, Terumo. Dr Garbo: Consultant Boston Scientific, Terumo, Philips Volcano, IMDS, and CID-ALVIMEDICA. Dr Grantham: Speaking fees, travel reimbursement, and honoraria from Boston Scientific, Abbott Vascular, and Asahi Intecc. Institutional research grants Boston Scientific. Part-time employment and equity in Corindus Vascular Robotics. Dr Harnatty: Proctoring for Abbott, Boston Scientific, Medtronic, and Teleflex. Dr Harb: Consultant with Medtronic, speaker's honoraria from Medtronic and Cardinal Health. Dr Harding: Proctor/speaker for Boston Scientific, Abbott Vascular, and Bio-Excel; consultant/speaker for Medtronic and Asahi. Dr Hill: Speaker, consultant, and proctor for Boston Scientific and Abbott Vascular. Dr Jaffer: Sponsored research from Canon, and Siemens; consultant for Boston Scientific, Abbott Vascular, Siemens, and Philips. Massachusetts General Hospital has a patent licensing arrangement with Canon, and Dr Jaffer has the right to receive royalties. Dr Jussila: Consulting agreement with EPS Vascular, Boston Scientific, and Terumo. Dr Kalyanasundaram: Speaker, consultant, and proctor for Boston Scientific, Asahi, and Abbott Vascular. Dr Kandzari: Research/grant support: Medtronic, Boston Scientific, Biotronik; consulting honoraria: Medtronic, Boston Scientific, Biotronik, and CSI. Dr Kao: Speaker/proctor honoraria: Abbott Vascular, Asahi Intecc, Biotronik, Boston Scientific, Medtronic, Orbus Neich, and Terumo. Dr Karpaliotis: Honoraria Boston Scientific, Abiomed and Abbott Vascular. Dr Kornowski: Co-founder of NitiLoop. Dr Krestyaninov: Speaker and proctor honoraria from Abbott Vascular. Dr Laanmets: Consultant for Terumo. Dr Lee:

Speaker and proctorship honoraria from Abbott Vascular, Boston Scientific, and Medtronic. Dr Lefevre: Proctoring for Terumo. Dr Lim: Travel support from Asahi Intecc, Terumo, Kaneka, Boston Scientific, and Abbott Vascular. Dr Lo: Travel support from Bioexcel and Abbott; speaker honoraria from Abbott, Boston Scientific, and Bioexcel; proctorship fees from Bioexcel and Boston Scientific. Dr Lombardi: Speaking fees, honoraria, and travel expense reimbursement from Boston Scientific, Asahi-Intecc, Teleflex, Siemens, and Abbott Vascular; equity holder in Corindus Vascular Robotics; spouse employed by Phillips. Dr Nicholson: Advisory boards and consulting: Abbott Vascular, Boston Scientific, Medtronic, and Corindus. Dr Olivecrona: Lecture/proctor honoraria: Biotronik, EPS vascular, Biosensors, and Edwards Lifesciences. Dr Postu: Advisory board: Medtronic; proctor: Boston Scientific; consultant: Terumo. Dr Quadros: Education support from Medtronic, Abbott Vascular, Boston Scientific, and Biotronic, and research grants from Medtronic. Dr Quesada: Proctor for Boston Scientific. Dr Saghatelian: Consulting/speaker honoraria from Asahi Intecc. Dr Trinidad: Proctor and Speaker for Boston Scientific and Abbott Vascular. Dr Smith: Speaker fees, honoraria, proctorship fees, Boston Scientific, Abbott Vascular, Vascular Perspectives, and Biosensors International. Dr Stone: Reports having served as a consultant to: Matrizyme, Miracor, Neovasc, V-wave, Shockwave, Valfix, TherOx, Reva, Vascular Dynamics, Robocath, HeartFlow, Gore, Ablative Solutions, and Ancora; having received speaker honoraria from Amaranth and Terumo; holding equity in Ancora, Cagent, Qool Therapeutics, Aria, Caliber, MedFocus family of funds, Biostar family of funds, Applied Therapeutics, and SpectraWAVE; serving as a director in SpectraWAVE; and that his employer, Columbia University, receives royalties for sale of the MitraClip from Abbott. Dr Strange: Consulting fees from Abbott and Boston Scientific. Dr Tammam: Proctor for Boston Scientific, Terumo and Asahi. Dr Ungi: CTO Proctor and consultant for Boston Scientific. Dr Vo: Consultant for Abbott Vascular, Canadian Hospital Specialties, and Teleflex. Dr Wollmuth: Proctor/consultant for Abbott Vascular, Boston Scientific, and Asahi Intecc. Dr Wu: Consultant fees and speaker honorarium from Abbott and Boston Scientific, and research grant from Asahi. Dr Wyman: Consultant/honoraria from Abbott, Abiomed, and Boston Scientific. Dr Yeh: Consulting/advisory board: Abbott Vascular, Asahi Intecc, Boston Scientific, Medtronic, and Teleflex. Research grants: Abbott Vascular, Abiomed, and Boston Scientific. Dr Rinfret: Research support from SoundBite Medical; consultant, proctor and/or speaker for Abiomed, Boston Scientific, Abbott, and Teleflex. The other authors report no conflicts.

REFERENCES

- Werner GS, Martin-Yuste V, Hildick-Smith D, Boudou N, Sianos G, Gelev V, Rumoroso JR, Erglis A, Christiansen EH, Escaned J, et al; EUROCTO trial investigators. A randomized multicentre trial to compare revascularization with optimal medical therapy for the treatment of chronic total coronary occlusions. *Eur Heart J*. 2018;39:2484–2493. doi: 10.1093/eurheartj/ehy220
- Obedinskiy AA, Kretov EI, Boukhris M, Kurbatov VP, Osiev AG, Ibn Elhadj Z, Obedinskaya NR, Kasbaoui S, Grazhdankin IO, Prokhorikhin AA, et al. The IMPACTOR-CTO Trial. *JACC Cardiovasc Interv*. 2018;11:1309–1311. doi: 10.1016/j.jcin.2018.04.017
- Sapontis J, Salisbury AC, Yeh RW, Cohen DJ, Hirai T, Lombardi W, McCabe JM, Karpaliotis D, Moses J, Nicholson WJ, et al. Early procedural and health status outcomes after chronic total occlusion angioplasty: a report from the OPEN-CTO Registry (Outcomes, Patient Health Status, and Efficiency in Chronic Total Occlusion Hybrid Procedures). *JACC Cardiovasc Interv*. 2017;10:1523–1534. doi: 10.1016/j.jcin.2017.05.065
- Christakopoulos GE, Christopoulos G, Carlino M, Jeroudi OM, Roesle M, Rangan BV, Abdullah S, Grodin J, Kumbhani DJ, Vo M, et al. Meta-analysis of clinical outcomes of patients who underwent percutaneous coronary interventions for chronic total occlusions. *Am J Cardiol*. 2015;115:1367–1375. doi: 10.1016/j.amjcard.2015.02.038
- Joyal D, Afilalo J, Rinfret S. Effectiveness of recanalization of chronic total occlusions: a systematic review and meta-analysis. *Am Heart J*. 2010;160:179–187. doi: 10.1016/j.ahj.2010.04.015
- Ybarra LF, Dautov R, Gibrat C, Dandona S, Rinfret S. Midterm angina-related quality of life benefits after percutaneous coronary intervention of chronic total occlusions. *Can J Cardiol*. 2017;33:1668–1674. doi: 10.1016/j.cjca.2017.08.008
- Lee SW, Lee PH, Ahn JM, Park DW, Yun SC, Han S, Kang H, Kang SJ, Kim YH, Lee CW, et al. Randomized trial evaluating percutaneous coronary intervention for the treatment of chronic total occlusion: the DECISION-CTO Trial. *Circulation*. 139:1674–1683. doi: 10.1161/CIRCULATIONAHA.118.031313
- Mashayekhi K, Neuser H, Kraus A, Zimmer M, Dalibor J, Akin I, Werner G, Aurel T, Neumann FJ, Behnes M. Successful percutaneous coronary intervention improves cardiopulmonary exercise capacity in patients with chronic total occlusions. *J Am Coll Cardiol*. 2017;69:1095–1096. doi: 10.1016/j.jacc.2016.12.017
- Bruckel JT, Jaffer FA, O'Brien C, Stone L, Pomerantsev E, Yeh RW. Angina severity, depression, and response to percutaneous revascularization in patients with chronic total occlusion of coronary arteries. *J Invasive Cardiol*. 2016;28:44–51.
- Werner GS, Ferrari M, Heinke S, Kuethe F, Surber R, Richartz BM, Figulla HR. Angiographic assessment of collateral connections in comparison with invasively determined collateral function in chronic coronary occlusions. *Circulation*. 2003;107:1972–1977. doi: 10.1161/01.CIR.0000061953.72662.3A
- Sachdeva R, Agrawal M, Flynn SE, Werner GS, Uretsky BF. The myocardium supplied by a chronic total occlusion is a persistently ischemic zone. *Catheter Cardiovasc Interv*. 2014;83:9–16. doi: 10.1002/ccd.25001
- Galassi AR, Boukhris M, Toma A, Elhadj Z, Laroussi L, Gaemperli O, Behnes M, Akin I, Lüscher TF, Neumann FJ, et al. Percutaneous coronary intervention of chronic total occlusions in patients with low left ventricular ejection fraction. *JACC Cardiovasc Interv*. 2017;10:2158–2170. doi: 10.1016/j.jcin.2017.06.058
- Megaly M, Saad M, Tajti P, Burke MN, Chavez I, Gössl M, Lips D, Mooney M, Poulouse A, Sorajja P, et al. Meta-analysis of the impact of successful chronic total occlusion percutaneous coronary intervention on left ventricular systolic function and reverse remodeling. *J Interv Cardiol*. 2018;31:562–571. doi: 10.1111/joic.12538
- Henriques JP, Hoebbers LP, Råmunddal T, Laanmets P, Eriksen E, Bax M, Ioanes D, Suttrop MJ, Strauss BH, Barbato E, et al; EXPLORE Trial Investigators. Percutaneous intervention for concurrent chronic total occlusions in patients with STEMI: the EXPLORE Trial. *J Am Coll Cardiol*. 2016;68:1622–1632. doi: 10.1016/j.jacc.2016.07.744
- Mashayekhi K, Nührenberg TG, Toma A, Gick M, Ferenc M, Hochholzer W, Comberg T, Rothe J, Valina CM, Löffelhardt N, et al. A randomized trial to assess regional left ventricular function after stent implantation in chronic total occlusion: the REVASC Trial. *JACC Cardiovasc Interv*. 2018;11:1982–1991. doi: 10.1016/j.jcin.2018.05.041
- Nombela-Franco L, Mitroi CD, Fernández-Lozano I, García-Touchard A, Toquero J, Castro-Urda V, Fernández-Díaz JA, Perez-Pereira E, Beltrán-Correas P, Segovia J, et al. Ventricular arrhythmias among implantable cardioverter-defibrillator recipients for primary prevention: impact of chronic total coronary occlusion (VACTO Primary Study). *Circ Arrhythm Electrophysiol*. 2012;5:147–154. doi: 10.1161/CIRCEP.111.968008
- Nombela-Franco L, Iannaccone M, Anguera I, Amat-Santos IJ, Sanchez-Garcia M, Bautista D, Calvelo MN, Di Marco A, Moretti C, Pozzi R, et al. Impact of chronic total coronary occlusion on recurrence of ventricular arrhythmias in ischemic secondary prevention implantable cardioverter-defibrillator recipients (VACTO Secondary Study): insights from coronary angiogram and electrogram analysis. *JACC Cardiovasc Interv*. 2017;10:879–888. doi: 10.1016/j.jcin.2017.02.008
- Di Marco A, Paglino G, Oloriz T, Maccabelli G, Baratto F, Vergara P, Bisceglia C, Anguera I, Sala S, Sora N, et al. Impact of a chronic total occlusion in an infarct-related artery on the long-term outcome of ventricular tachycardia ablation. *J Cardiovasc Electrophysiol*. 2015;26:532–539. doi: 10.1111/jce.12622
- O'Connor SA, Garot P, Sanguineti F, Hoebbers LP, Untersee T, Benamer H, Chevalier B, Hovasse T, Morice MC, Lefèvre T, et al. Meta-analysis of the impact on mortality of noninfarct-related artery coronary chronic total occlusion in patients presenting with ST-segment elevation myocardial infarction. *Am J Cardiol*. 2015;116:8–14. doi: 10.1016/j.amjcard.2015.03.031
- George S, Cockburn J, Clayton TC, Ludman P, Cotton J, Spratt J, Redwood S, de Belder M, de Belder A, Hill J, et al; British Cardiovascular Intervention Society; National Institute for Cardiovascular Outcomes Research. Long-term follow-up of elective chronic total coronary occlusion angioplasty: analysis from the U.K. Central Cardiac Audit Database. *J Am Coll Cardiol*. 2014;64:235–243. doi: 10.1016/j.jacc.2014.04.040
- Tomasello SD, Boukhris M, Giubilato S, Marzà F, Garbo R, Contegiacomo G, Marzocchi A, Niccoli G, Gagnor A, Varbella F, et al. Management strategies in patients affected by chronic total occlusions: results from the Italian Registry of Chronic Total Occlusions. *Eur Heart J*. 2015;36:3189–3198. doi: 10.1093/eurheartj/ehv450
- Yang JH, Kim BS, Jang WJ, Ahn J, Park TK, Song YB, Hahn JY, Choi JH, Lee SH, Gwon HC, et al. Optimal medical therapy vs. percutaneous coronary intervention for patients with coronary chronic total oc-

- clusion - a propensity-matched analysis. *Circ J*. 2016;80:211–217. doi: 10.1253/circj.CJ-15-0673
23. Jang WJ, Yang JH, Choi SH, Song YB, Hahn JY, Choi JH, Kim WS, Lee YT, Gwon HC. Long-term survival benefit of revascularization compared with medical therapy in patients with coronary chronic total occlusion and well-developed collateral circulation. *JACC Cardiovasc Interv*. 2015;8:271–279. doi: 10.1016/j.jcin.2014.10.010
 24. Garcia S, Sandoval Y, Roukoz H, Adabag S, Canoniero M, Yannopoulos D, Brilakis ES. Outcomes after complete versus incomplete revascularization of patients with multivessel coronary artery disease: a meta-analysis of 89,883 patients enrolled in randomized clinical trials and observational studies. *J Am Coll Cardiol*. 2013;62:1421–1431. doi: 10.1016/j.jacc.2013.05.033
 25. Goel PK, Khanna R, Pandey CM, Ashfaq F. Long-term outcomes post chronic total occlusion intervention-implications of completeness of revascularization. *J Interv Cardiol*. 2018;31:293–301. doi: 10.1111/joic.12480
 26. Levine GN, Bates ER, Blankenship JC, Bailey SR, Bittl JA, Cercek B, Chambers CE, Ellis SG, Guyton RA, Hollenberg SM, et al. 2011 ACCF/AHA/SCAI Guideline for Percutaneous Coronary Intervention: a report of the American College of Cardiology Foundation/American Heart Association Task Force on Practice Guidelines and the Society for Cardiovascular Angiography and Interventions. *Circulation*. 2011;124:e574–e651. doi: 10.1161/CIR.0b013e31823ba622
 27. Neumann FJ, Sousa-Uva M, Ahlsson A, Alfonso F, Banning AP, Benedetto U, Byrne RA, Collet JP, Falk V, Head SJ, et al; ESC Scientific Document Group. 2018 ESC/EACTS Guidelines on myocardial revascularization. *Eur Heart J*. 2019;40:87–165. doi: 10.1093/eurheartj/ehy394
 28. Azzalini L, Agostoni P, Benincasa S, Knaepen P, Schumacher SP, Dens J, Maeremans J, Kraaijeveld AO, Timmers L, Behnes M, et al. Retrograde chronic total occlusion percutaneous coronary intervention through ipsilateral collateral channels: a multicenter registry. *JACC Cardiovasc Interv*. 2017;10:1489–1497. doi: 10.1016/j.jcin.2017.06.002
 29. Brilakis ES, Grantham JA, Rinfret S, Wyman RM, Burke MN, Karpaliotis D, Lembo N, Pershad A, Kandzari DE, Buller CE, et al. A percutaneous treatment algorithm for crossing coronary chronic total occlusions. *JACC Cardiovasc Interv*. 2012;5:367–379. doi: 10.1016/j.jcin.2012.02.006
 30. Brilakis ES. *Manual of Coronary Chronic Total Occlusion Interventions. A Step-By-Step Approach*. 2nd ed. London, United Kingdom: Elsevier; 2017.
 31. Suzuki Y, Tsuchikane E, Katoh O, Muramatsu T, Muto M, Kishi K, Hamazaki Y, Oikawa Y, Kawasaki T, Okamura A. Outcomes of percutaneous coronary interventions for chronic total occlusion performed by highly experienced Japanese specialists: the first report from the Japanese CTO-PCI Expert Registry. *JACC Cardiovasc Interv*. 2017;10:2144–2154.
 32. Ghoshhajra BB, Takx RAP, Stone LL, Girard EE, Brilakis ES, Lombardi WL, Yeh RW, Jaffer FA. Real-time fusion of coronary CT angiography with x-ray fluoroscopy during chronic total occlusion PCI. *Eur Radiol*. 2017;27:2464–2473. doi: 10.1007/s00330-016-4599-5
 33. Karatasakis A, Danek BA, Karpaliotis D, Alaswad K, Jaffer FA, Yeh RW, Patel MP, Bahadorani JN, Wyman RM, Lombardi WL, et al. Impact of proximal cap ambiguity on outcomes of chronic total occlusion percutaneous coronary intervention: insights from a multicenter US registry. *J Invasive Cardiol*. 2016;28:391–396.
 34. Fujino A, Otsuji S, Hasegawa K, Arita T, Takiuchi S, Fujii K, Yabuki M, Ibuki M, Nagayama S, Ishibuchi K, et al. Accuracy of J-CTO score derived from computed tomography versus angiography to predict successful percutaneous coronary intervention. *JACC Cardiovasc Imaging*. 2018;11(2 pt 1):209–217. doi: 10.1016/j.jcmg.2017.01.028
 35. Harding SA, Wu EB, Lo S, Lim ST, Ge L, Chen JY, Quan J, Lee SW, Kao HL, Tsuchikane E. A new algorithm for crossing chronic total occlusions from the Asia Pacific Chronic Total Occlusion Club. *JACC Cardiovasc Interv*. 2017;10:2135–2143. doi: 10.1016/j.jcin.2017.06.071
 36. Azzalini L, Carlino M, Brilakis ES, Vo M, Rinfret S, Uretsky BF, Karpaliotis D, Colombo A. Subadventitial techniques for chronic total occlusion percutaneous coronary intervention: the concept of “vessel architecture.” *Catheter Cardiovasc Interv*. 2018;91:725–734. doi: 10.1002/ccd.27025
 37. Galassi AR, Tomasello SD, Crea F, Costanzo L, Campiano MB, Marzà F, Tamburino C. Transient impairment of vasomotion function after successful chronic total occlusion recanalization. *J Am Coll Cardiol*. 2012;59:711–718. doi: 10.1016/j.jacc.2011.10.894
 38. McEntegart MB, Badar AA, Ahmad FA, Shaikat A, MacPherson M, Irving J, Strange J, Bagnall AJ, Hanratty CG, Walsh SJ, et al. The collateral circulation of coronary chronic total occlusions. *EuroIntervention*. 2016;11:e1596–e1603. doi: 10.4244/EIJV11114A310
 39. Huang CC, Lee CK, Meng SW, Hung CS, Chen YH, Lin MS, Yeh CF, Kao HL. Collateral channel size and tortuosity predict retrograde percutaneous coronary intervention success for chronic total occlusion. *Circ Cardiovasc Interv*. 2018;11:e005124. doi: 10.1161/CIRCINTERVENTIONS.117.005124
 40. Dautov R, Urena M, Nguyen CM, Gibart C, Rinfret S. Safety and effectiveness of the surfing technique to cross septal collateral channels during retrograde chronic total occlusion percutaneous coronary intervention. *EuroIntervention*. 2017;12:e1859–e1867. doi: 10.4244/EIJ-D-16-00650
 41. Tajti P, Karatasakis A, Karpaliotis D, Alaswad K, Jaffer FA, Yeh RW, Patel M, Mahmud E, Choi JW, Doing AH, et al. Retrograde CTO-PCI of native coronary arteries via left internal mammary artery grafts: insights from a multicenter U.S. registry. *J Invasive Cardiol*. 2018;30:89–96.
 42. Rathore S, Katoh O, Matsuo H, Terashima M, Tanaka N, Kinoshita Y, Kimura M, Tsuchikane E, Nasu K, Ehara M, et al. Retrograde percutaneous recanalization of chronic total occlusion of the coronary arteries: procedural outcomes and predictors of success in contemporary practice. *Circ Cardiovasc Interv*. 2009;2:124–132. doi: 10.1161/CIRCINTERVENTIONS.108.838862
 43. Benincasa S, Azzalini L, Carlino M, Bellini B, Giannini F, Zhao X, Colombo A. Outcomes of the retrograde approach through epicardial versus non-epicardial collaterals in chronic total occlusion percutaneous coronary intervention. *Cardiovasc Revasc Med*. 2017;18:393–398. doi: 10.1016/j.carrev.2017.03.013
 44. Christopoulos G, Wyman RM, Alaswad K, Karpaliotis D, Lombardi W, Grantham JA, Yeh RW, Jaffer FA, Cipher DJ, Rangan BV, et al. Clinical utility of the Japan-chronic total occlusion score in coronary chronic total occlusion interventions: results from a multicenter registry. *Circ Cardiovasc Interv*. 2015;8:e002171. doi: 10.1161/CIRCINTERVENTIONS.114.002171
 45. Azzalini L, Ojeda S, Karatasakis A, Maeremans J, Tanabe M, La Manna A, Dautov R, Ybarra LF, Benincasa S, Bellini B, et al. Long-term outcomes of percutaneous coronary intervention for chronic total occlusion in patients who have undergone coronary artery bypass grafting vs those who have not. *Can J Cardiol*. 2018;34:310–318. doi: 10.1016/j.cjca.2017.12.016
 46. Morino Y, Abe M, Morimoto T, Kimura T, Hayashi Y, Muramatsu T, Ochiai M, Noguchi Y, Kato K, Shibata Y, et al; J-CTO Registry Investigators. Predicting successful guidewire crossing through chronic total occlusion of native coronary lesions within 30 minutes: the J-CTO (Multicenter CTO Registry in Japan) score as a difficulty grading and time assessment tool. *JACC Cardiovasc Interv*. 2011;4:213–221. doi: 10.1016/j.jcin.2010.09.024
 47. Tanaka H, Morino Y, Abe M, Kimura T, Hayashi Y, Muramatsu T, Ochiai M, Noguchi Y, Kato K, Shibata Y, et al. Impact of J-CTO score on procedural outcome and target lesion revascularisation after percutaneous coronary intervention for chronic total occlusion: a substudy of the J-CTO Registry (Multicentre CTO Registry in Japan). *EuroIntervention*. 2016;11:981–988. doi: 10.4244/EIJV1119A202
 48. Christopoulos G, Kandzari DE, Yeh RW, Jaffer FA, Karpaliotis D, Wyman MR, Alaswad K, Lombardi W, Grantham JA, Moses J, et al. Development and validation of a novel scoring system for predicting technical success of chronic total occlusion percutaneous coronary interventions: the PROGRESS CTO (Prospective Global Registry for the Study of Chronic Total Occlusion Intervention) Score. *JACC Cardiovasc Interv*. 2016;9:1–9. doi: 10.1016/j.jcin.2015.09.022
 49. Maeremans J, Spratt JC, Knaepen P, Walsh S, Agostoni P, Wilson W, Avran A, Faurie B, Bressollette E, Kayaert P, et al. Towards a contemporary, comprehensive scoring system for determining technical outcomes of hybrid percutaneous chronic total occlusion treatment: the RECHARGE score. *Catheter Cardiovasc Interv*. 2018;91:192–202. doi: 10.1002/ccd.27092
 50. Alessandrino G, Chevalier B, Lefèvre T, Sanguineti F, Garot P, Untersee T, Hovasse T, Morice MC, Louvard Y. A clinical and angiographic scoring system to predict the probability of successful first-attempt percutaneous coronary intervention in patients with total chronic coronary occlusion. *JACC Cardiovasc Interv*. 2015;8:1540–1548. doi: 10.1016/j.jcin.2015.07.009
 51. Galassi AR, Boukhris M, Azzarelli S, Castaing M, Marzà F, Tomasello SD. Percutaneous coronary revascularization for chronic total occlusions: a novel predictive score of technical failure using advanced technologies. *JACC Cardiovasc Interv*. 2016;9:911–922. doi: 10.1016/j.jcin.2016.01.036
 52. Ellis SG, Burke MN, Murad MB, Graham JJ, Badawi R, Toma C, Meltzer H, Nair R, Buller C, Whitlow PL, CAPS Group. Predictors of successful hybrid-approach chronic total coronary artery occlusion stenting: an improved model with novel correlates. *JACC Cardiovasc Interv*. 2017;10:1089–1098. doi: 10.1016/j.jcin.2017.03.016
 53. Khanna R, Pandey CM, Bedi S, Ashfaq F, Goel PK. A weighted angiographic scoring model (W-CTO score) to predict success of antegrade wire crossing in chronic total occlusion: analysis from a single centre. *AsiaIntervention*. 2018;4:18–25.

54. Szigyarto Z, Rampat R, Werner GS, Ho C, Reifart N, Lefevre T, Louvard Y, Avran A, Kambis M, Buettner HJ, et al. Derivation and validation of a chronic total coronary occlusion intervention procedural success score from the 20,000-patient EuroCTO Registry: the EuroCTO (CASTLE) Score. *JACC Cardiovasc Interv*. 2019;12:335–342. doi: 10.1016/j.jcin.2018.11.020
55. Opolski MP, Achenbach S, Schubbäck A, Rolf A, Möllmann H, Nef H, Rixe J, Renker M, Witkowski A, Kepka C, et al. Coronary computed tomographic prediction rule for time-efficient guidewire crossing through chronic total occlusion: insights from the CT-RECTOR multicenter registry (Computed Tomography Registry of Chronic Total Occlusion Revascularization). *JACC Cardiovasc Interv*. 2015;8:257–267. doi: 10.1016/j.jcin.2014.07.031
56. Yu CW, Lee HJ, Suh J, Lee NH, Park SM, Park TK, Yang JH, Song YB, Hahn JY, Choi SH, et al. Coronary computed tomography angiography predicts guidewire crossing and success of percutaneous intervention for chronic total occlusion: Korean Multicenter CTO CT Registry Score as a tool for assessing difficulty in chronic total occlusion percutaneous coronary intervention. *Circ Cardiovasc Imaging*. 2017;10:e005800.
57. Karatasakis A, Danek BA, Karpaliotis D, Alaswad K, Jaffer FA, Yeh RW, Patel M, Bahadorani JN, Lombardi WL, Wyman RM, et al. Comparison of various scores for predicting success of chronic total occlusion percutaneous coronary intervention. *Int J Cardiol*. 2016;224:50–56. doi: 10.1016/j.ijcard.2016.08.317
58. Danek BA, Karatasakis A, Karpaliotis D, Alaswad K, Yeh RW, Jaffer FA, Patel MP, Mahmud E, Lombardi WL, Wyman MR, et al. Development and validation of a scoring system for predicting periprocedural complications during percutaneous coronary interventions of chronic total occlusions: the Prospective GLOBAL Registry for the Study of Chronic Total Occlusion Intervention (PROGRESS CTO) Complications Score. *J Am Heart Assoc*. 2016;5:e004272.
59. Azzalini L, Uretsky B, Brilakis ES, Colombo A, Carlino M. Contrast modulation in chronic total occlusion percutaneous coronary intervention. *Catheter Cardiovasc Interv*. 2019;93:E24–E29. doi: 10.1002/ccd.27869
60. Tajti P, Karpaliotis D, Alaswad K, Jaffer FA, Yeh RW, Patel M, Mahmud E, Choi JW, Burke MN, Doing AH, et al. The hybrid approach to chronic total occlusion percutaneous coronary intervention: update from the PROGRESS CTO Registry. *JACC Cardiovasc Interv*. 2018;11:1325–1335. doi: 10.1016/j.jcin.2018.02.036
61. Maeremans J, Walsh S, Knaapen P, Spratt JC, Avran A, Hanratty CG, Faurie B, Agostoni P, Bressollette E, Kayaert P, et al. The hybrid algorithm for treating chronic total occlusions in Europe: the RECHARGE Registry. *J Am Coll Cardiol*. 2016;68:1958–1970. doi: 10.1016/j.jacc.2016.08.034
62. Wilson WM, Walsh SJ, Yan AT, Hanratty CG, Bagnall AJ, Egred M, Smith E, Oldroyd KG, McEntegart M, Irving J, et al. Hybrid approach improves success of chronic total occlusion angioplasty. *Heart*. 2016;102:1486–1493. doi: 10.1136/heartjnl-2015-308891
63. Colombo A, Mikhail GW, Michev I, Iakovou I, Airoidi F, Chieffo A, Rogacka R, Carlino M, Montorfano M, Sangiorgi GM, et al. Treating chronic total occlusions using subintimal tracking and reentry: the STAR technique. *Catheter Cardiovasc Interv*. 2005;64:407–411; discussion 412.
64. Valenti R, Vergara R, Migliorini A, Parodi G, Carrabba N, Cerisano G, Dovellini EV, Antoniucci D. Predictors of reocclusion after successful drug-eluting stent-supported percutaneous coronary intervention of chronic total occlusion. *J Am Coll Cardiol*. 2013;61:545–550. doi: 10.1016/j.jacc.2012.10.036
65. Godino C, Latib A, Economou FI, Al-Lamee R, Ielasi A, Bassanelli G, Figini F, Chieffo A, Montorfano M, Colombo A, et al. Coronary chronic total occlusions: mid-term comparison of clinical outcome following the use of the guided-STAR technique and conventional antegrade approaches. *Catheter Cardiovasc Interv*. 2012;79:20–27. doi: 10.1002/ccd.23058
66. Hirai T, Grantham JA, Sapontis J, Cohen DJ, Marso SP, Lombardi W, Karpaliotis D, Moses J, Nicholson WJ, Pershad A, et al; OPEN CTO Study Group. Impact of subintimal plaque modification procedures on health status after unsuccessful chronic total occlusion angioplasty. *Catheter Cardiovasc Interv*. 2018;91:1035–1042. doi: 10.1002/ccd.27380
67. Wilson WM, Bagnall AJ, Spratt JC. In case of procedure failure: facilitating future success. *Interv Cardiol*. 2013;5:521–531.
68. Goleski PJ, Nakamura K, Liebeskind E, Salisbury AC, Grantham JA, McCabe JM, Lombardi WL. Revascularization of coronary chronic total occlusions with subintimal tracking and reentry followed by deferred stenting: experience from a high-volume referral center. *Catheter Cardiovasc Interv*. 2019;93:191–198. doi: 10.1002/ccd.27783
69. Whitlow PL, Burke MN, Lombardi WL, Wyman RM, Moses JW, Brilakis ES, Heuser RR, Rihal CS, Lansky AJ, Thompson CA; FAST-CTOs Trial Investi-
- gators. Use of a novel crossing and re-entry system in coronary chronic total occlusions that have failed standard crossing techniques: results of the FAST-CTOs (Facilitated Antegrade Steering Technique in Chronic Total Occlusions) trial. *JACC Cardiovasc Interv*. 2012;5:393–401. doi: 10.1016/j.jcin.2012.01.014
70. Karacsonyi J, Tajti P, Rangan BV, Halligan SC, Allen RH, Nicholson WJ, Harvey JE, Spaedy AJ, Jaffer FA, Grantham JA, et al. Randomized comparison of a crossboss first versus standard wire escalation strategy for crossing coronary chronic total occlusions: the CrossBoss First Trial. *JACC Cardiovasc Interv*. 2018;11:225–233. doi: 10.1016/j.jcin.2017.10.023
71. Galassi AR, Boukhris M, Tomasello SD, Marzà F, Azzarelli S, Giubilato S, Khamis H. Long-term clinical and angiographic outcomes of the mini-STAR technique as a bailout strategy for percutaneous coronary intervention of chronic total occlusion. *Can J Cardiol*. 2014;30:1400–1406. doi: 10.1016/j.cjca.2014.07.016
72. Karatasakis A, Danek BA, Karacsonyi J, Azzalini L, Carlino M, Rinfret S, Vo M, Rangan BV, Burke MN, Banerjee S, et al. Mid-term outcomes of chronic total occlusion percutaneous coronary intervention with subadventitial vs. intraplaque crossing: a systematic review and meta-analysis. *Int J Cardiol*. 2018;253:29–34. doi: 10.1016/j.ijcard.2017.08.044
73. Wilson WM, Walsh SJ, Bagnall AJ, Yan AT, Hanratty CG, Egred M, Smith E, Oldroyd KG, McEntegart M, Irving J, et al. One-year outcomes after successful chronic total occlusion percutaneous coronary intervention: the impact of dissection re-entry techniques. *Catheter Cardiovasc Interv*. 2017;90:703–712. doi: 10.1002/ccd.26980
74. Maeremans J, Dens J, Spratt JC, Bagnall AJ, Stuijffand W, Nap A, Agostoni P, Wilson W, Hanratty CG, Wilson S, et al; RECHARGE Investigators. Antegrade dissection and reentry as part of the hybrid chronic total occlusion revascularization strategy: a subanalysis of the RECHARGE Registry (Registry of CrossBoss and Hybrid Procedures in France, the Netherlands, Belgium and United Kingdom). *Circ Cardiovasc Interv*. 2017;10:e004791.
75. Azzalini L, Dautov R, Brilakis ES, Ojeda S, Benincasa S, Bellini B, Karatasakis A, Chavarria J, Rangan BV, Pan M, et al. Procedural and longer-term outcomes of wire- versus device-based antegrade dissection and re-entry techniques for the percutaneous revascularization of coronary chronic total occlusions. *Int J Cardiol*. 2017;231:78–83. doi: 10.1016/j.ijcard.2016.11.273
76. Danek BA, Karatasakis A, Karpaliotis D, Alaswad K, Yeh RW, Jaffer FA, Patel M, Bahadorani J, Lombardi WL, Wyman MR, et al. Use of antegrade dissection re-entry in coronary chronic total occlusion percutaneous coronary intervention in a contemporary multicenter registry. *Int J Cardiol*. 2016;214:428–437. doi: 10.1016/j.ijcard.2016.03.215
77. Joyal D, Thompson CA, Grantham JA, Buller CE, Rinfret S. The retrograde technique for recanalization of chronic total occlusions: a step-by-step approach. *JACC Cardiovasc Interv*. 2012;5:1–11. doi: 10.1016/j.jcin.2011.10.011
78. Sakakura K, Nakano M, Otsuka F, Yahagi K, Kutys R, Ladich E, Finn AV, Kolodgie FD, Virmani R. Comparison of pathology of chronic total occlusion with and without coronary artery bypass graft. *Eur Heart J*. 2014;35:1683–1693. doi: 10.1093/eurheartj/ehd422
79. Wu EB, Tsuchikane E, Lo S, Lim TS, Ge L, Che JY, Qian J, Lee SW, Harding S, Kao HL. Retrograde algorithm for chronic total occlusion from the Asia Pacific Chronic Total Occlusion club. *AsiaIntervention*. 2018;4:98–107.
80. Huang Z, Zhang B, Chai W, Ma D, Liao H, Zhong Z, Wang F, Lin J. Usefulness and safety of a novel modification of the retrograde approach for the long tortuous chronic total occlusion of coronary arteries. *Int Heart J*. 2017;58:351–356. doi: 10.1536/ihj.16-337
81. Galassi AR, Werner GS, Boukhris M, Azzalini L, Mashayekhi K, Carlino M, Avran A, Konstantinidis NV, Grancini L, Bryniarski L, et al. Percutaneous recanalization of chronic total occlusions: 2019 consensus document from the EuroCTO Club. *EuroIntervention*. 2019;15:198–208.
82. Galassi AR, Sianos G, Werner GS, Escaned J, Tomasello SD, Boukhris M, Castaing M, Büttner JH, Bufe A, Kalnins A, et al; Euro CTO Club. Retrograde recanalization of chronic total occlusions in Europe: procedural, in-hospital, and long-term outcomes from the Multicenter ERCTO Registry. *J Am Coll Cardiol*. 2015;65:2388–2400. doi: 10.1016/j.jacc.2015.03.566
83. Galassi AR, Sumitsuji S, Boukhris M, Brilakis ES, Di Mario C, Garbo R, Spratt JC, Christiansen EH, Gagnor A, Avran A, et al. Utility of intravascular ultrasound in percutaneous revascularization of chronic total occlusions: an overview. *JACC Cardiovasc Interv*. 2016;9:1979–1991. doi: 10.1016/j.jcin.2016.06.057

84. Vo MN, Karpaliotis D, Brilakis ES. "Move the cap" technique for ambiguous or impenetrable proximal cap of coronary total occlusion. *Catheter Cardiovasc Interv*. 2016;87:742–748. doi: 10.1002/ccd.26079
85. Karpaliotis D, Lembo N, Kalynych A, Carlson H, Lombardi WL, Anderson CN, Rinehart S, Kirkland B, Shemwell KC, Kandzari DE. Development of a high-volume, multiple-operator program for percutaneous chronic total coronary occlusion revascularization: procedural, clinical, and cost-utilization outcomes. *Catheter Cardiovasc Interv*. 2013;82:1–8. doi: 10.1002/ccd.24387
86. Brilakis ES, Banerjee S, Karpaliotis D, Lombardi WL, Tsai TT, Shunk KA, Kennedy KF, Spertus JA, Holmes DR Jr, Grantham JA. Procedural outcomes of chronic total occlusion percutaneous coronary intervention: a report from the NCDR (National Cardiovascular Data Registry). *JACC Cardiovasc Interv*. 2015;8:245–253. doi: 10.1016/j.jcin.2014.08.014
87. Kinnaird T, Gallagher S, Cockburn J, Sirker A, Ludman P, de Belder M, Smith E, Anderson R, Strange J, Mamas M, et al; British Cardiovascular Intervention Society and the National Institute for Cardiovascular Outcomes Research. Procedural success and outcomes with increasing use of enabling strategies for chronic total occlusion intervention. *Circ Cardiovasc Interv*. 2018;11:e006436. doi: 10.1161/CIRCINTERVENTIONS.118.006436
88. Habara M, Tsuchikane E, Muramatsu T, Kashima Y, Okamura A, Mutoh M, Yamane M, Oida A, Oikawa Y, Hasegawa K; Retrograde Summit Investigators. Comparison of percutaneous coronary intervention for chronic total occlusion outcome according to operator experience from the Japanese retrograde summit registry. *Catheter Cardiovasc Interv*. 2016;87:1027–1035. doi: 10.1002/ccd.26354
89. Konstantinidis NV, Werner GS, Deftereos S, DiMario C, Galassi AR, Buettner JH, Avran A, Reifart N, Goktekin O, Garbo R, et al; Euro CTO Club. Temporal trends in chronic total occlusion interventions in Europe. *Circ Cardiovasc Interv*. 2018;11:e006229. doi: 10.1161/CIRCINTERVENTIONS.117.006229
90. Wu EB, Tsuchikane E. The inherent catastrophic traps in retrograde CTO PCI. *Catheter Cardiovasc Interv*. 2018;91:1101–1109. doi: 10.1002/ccd.27104
91. Okamura A, Yamane M, Muto M, Matsubara T, Igarashi Y, Nakamura S, Muramatsu T, Fujita T, Oida A, Tsuchikane E. Complications during retrograde approach for chronic coronary total occlusion: sub-analysis of Japanese multicenter registry. *Catheter Cardiovasc Interv*. 2016;88:7–14. doi: 10.1002/ccd.26317
92. Kotsia AP, Brilakis ES, Karpaliotis D. Thrombin injection for sealing epicardial collateral perforation during chronic total occlusion percutaneous coronary interventions. *J Invasive Cardiol*. 2014;26:E124–E126.
93. Karatasakis A, Akhtar YN, Brilakis ES. Distal coronary perforation in patients with prior coronary artery bypass graft surgery: the importance of early treatment. *Cardiovasc Revasc Med*. 2016;17:412–417. doi: 10.1016/j.carrev.2016.05.014
94. Christopoulos G, Makke L, Christakopoulos G, Kotsia A, Rangan BV, Roesle M, Haagen D, Kumbhani DJ, Chambers CE, Kapadia S, et al. Optimizing radiation safety in the cardiac catheterization laboratory: a practical approach. *Catheter Cardiovasc Interv*. 2016;87:291–301. doi: 10.1002/ccd.25959
95. Hirshfeld JW Jr, Ferrari VA, Bengel FM, Bergersen L, Chambers CE, Einstein AJ, Eisenberg MJ, Fogel MA, Gerber TC, Haines DE, et al; Writing Committee Members; ACC Task Force On Expert Consensus Decision Pathways. 2018 ACC/HRS/NASCI/SCAI/SCCT expert consensus document on optimal use of ionizing radiation in cardiovascular imaging: best practices for safety and effectiveness. *Catheter Cardiovasc Interv*. 2018;92:E35–E97. doi: 10.1002/ccd.27659
96. Kim BK, Shin DH, Hong MK, Park HS, Rha SW, Mintz GS, Kim JS, Kim JS, Lee SJ, Kim HY, et al; CTO-IVUS Study Investigators. Clinical impact of intravascular ultrasound-guided chronic total occlusion intervention with zotarolimus-eluting versus biolimus-eluting stent implantation: randomized study. *Circ Cardiovasc Interv*. 2015;8:e002592. doi: 10.1161/CIRCINTERVENTIONS.115.002592
97. Tian NL, Gami SK, Ye F, Zhang JJ, Liu ZZ, Lin S, Ge Z, Shan SJ, You W, Chen L, et al. Angiographic and clinical comparisons of intravascular ultrasound- versus angiography-guided drug-eluting stent implantation for patients with chronic total occlusion lesions: two-year results from a randomised AIR-CTO study. *EuroIntervention*. 2015;10:1409–1417. doi: 10.4244/EIJV10I12A245
98. Karacsonyi J, Alaswad K, Jaffer FA, Yeh RW, Patel M, Bahadorani J, Karatasakis A, Danek BA, Doing A, Grantham JA, et al. Use of intravascular imaging during chronic total occlusion percutaneous coronary intervention: insights from a contemporary multicenter registry. *J Am Heart Assoc*. 2016;5:e003890.
99. Zhang J, Gao X, Kan J, Ge Z, Han L, Lu S, Tian N, Lin S, Lu Q, Wu X, et al. Intravascular ultrasound-guided versus angiography-guided implantation of drug-eluting stent in all-comers: the ULTIMATE trial. *J Am Coll Cardiol*. 2018;72:3126–3137.
100. Zivelonghi C, Suttrop MJ, Teeuwen K, van Kuijk JP, van der Heyden JAS, Eefting FD, Rensing BJ, Ten Berg JM, van den Brink FS, Benfari G, et al. Clinical implications of distal vessel stenosis after successful coronary chronic total occlusion recanalization. *JACC Cardiovasc Interv*. 2018;11:2343–2345. doi: 10.1016/j.jcin.2018.07.038